



ELSEVIER

Available online at [www.sciencedirect.com](http://www.sciencedirect.com)

# Inflammatory muscle diseases: a critical review on pathogenesis and therapies

Marinos C Dalakas

Based on unique clinicopathological criteria, the most common immune inflammatory muscle disorders include Dermatomyositis (DM), Polymyositis (PM), Necrotizing Myositis (NM), and sporadic Inclusion Body Myositis (sIBM). DM is undeniably a complement-mediated microangiopathy with destruction of capillaries, hypoperfusion, and inflammatory cell stress on the perifascicular regions. Necrotizing Myopathy is a poorly studied subacute myopathy triggered by toxic, viral, or autoimmune factors with macrophages as the final effector cells. In PM and IBM cytotoxic CD8-positive T-cells clonally expand *in situ* and invade MHC-I-expressing muscle fibers. In sIBM, in addition to autoimmune inflammation, there are degenerative features characterized by vacuolization and accumulation of stressor and amyloid-related molecules. Advances in the immunobiology of these disorders are discussed including the interaction between pro-inflammatory and  $\beta$ -amyloid or stressor proteins. A critical review regarding tissue biomarkers and strategies for more effective treatments are presented.

## Address

Department of Neurosciences, Imperial College, London, UK

Corresponding author: Dalakas, Marinos C ([m.dalakas@imperial.ac.uk](mailto:m.dalakas@imperial.ac.uk))

**Current Opinion in Pharmacology** 2010, **10**:1–7

This review comes from a themed issue on  
Musculoskeletal  
Edited by John D Isaacs and Patrick F Chinnery

1471-4892/\$ – see front matter  
© 2010 Elsevier Ltd. All rights reserved.

DOI [10.1016/j.coph.2010.03.001](https://doi.org/10.1016/j.coph.2010.03.001)

## Introduction

The most common inflammatory myopathies with distinct clinicopathologic features and clinical course include Dermatomyositis, Polymyositis, Inclusion Body Myositis, and Necrotizing Myositis (NM) [1–4,5\*]. Dermatomyositis (DM) presents with proximal muscle weakness accompanied or preceded by typical skin changes. Polymyositis (PM) is rare as a single entity, lacks a unique clinical phenotype and presents subacutely in people above the age of 18 with proximal muscle weakness and CK elevation. PM is frequently overdiagnosed; the most common disorders misdiagnosed as PM are: IBM, inflammatory dystrophies, and NM. Sporadic inclusion

body myositis (sIBM) has a distinct clinical phenotype characterized by weakness and atrophy of certain distal and proximal muscles. Necrotizing Myopathy (NM) has a multifactorial etiology; it may have an acute or subacute onset, can be severe, may have a seasonal variation or cancer association, and may be triggered by statins; it is often misdiagnosed as PM, toxic myopathy, or a metabolic myopathy owing to the acute onset of hyperCKemia.

This review outlines the fundamentally different pathology between these subsets as evolved the past few years, provides a critical analysis of the diagnostic markers, and summarizes the most significant developments on their pathogenesis as relate to therapeutic strategies.

## Immunopathology of DM: a critical reappraisal

An early event in the disease is the damage to the endothelial cells of endomysial capillaries mediated by complement activation and formation of membranolytic attack complexes (MAC), which causes lysis of the endothelial cells, destruction of capillaries, and muscle ischemia [1,2,6–10]. As a result, the number of capillaries is reduced throughout the muscle, while the lumen of the remaining ones is dilated to compensate for the ischemic process. The pathology is more pronounced in the outer layers of the fascicles probably due to hypoperfusion resulting in ‘perifascicular atrophy’. The complement activation triggers pro-inflammatory cytokines and cell recruitment, most notably interferon- $\gamma$ , CD4 + T-cells, B-cells, macrophages, and interferon- $\alpha/\beta$  [1,2,4,6–10,11,12]. Plasmacytoid dendritic cells [11] or formation of germinal-like centers can be seen, as recently demonstrated [13\*]. Gene array studies have demonstrated upregulation of  $\alpha/\beta$ -interferon and  $\gamma$ -interferon-inducible genes [11,12]. Production of IL-6 and the type-I interferon signature genes were recently proposed as biomarkers for disease activity in childhood DM [14\*]. Many of the perifascicular fibers are regenerating/degenerating and stain strongly with alkaline phosphatase, desmin, and NCAM; they also stain with antibodies against a variety of immune or stressor molecules [10], including TGF- $\beta$  [15], MHC-I,  $\alpha$ B-crystallin, cathepsins, amyloid precursor protein, STAT-1 triggered by interferon- $\gamma$  [16], and myxovirus resistance MxA protein triggered by  $\alpha/\beta$ -interferon [11]. Recently, the autoantibody against chromatin remodeler Mi-2, which is present in some DM patients, was strongly immunolocalized in the perifascicular fibers and in the regenerating muscle [17\*\*], confirming that the perifascicularly atrophic fibers are

## 2 Musculoskeletal

indeed regenerating and that Mi-2 may play a role in myofiber stability during the regenerating process.

This logical series of events centered around the undisputed complement-mediated microangiopathic process, is now challenged by Greenberg who, based on the gene array studies and the immunolocalization of MxA protein in the perifascicular regions, has theorized that the myofibers may be primarily injured by chronic overproduction of  $\alpha/\beta$ -interferon-inducible proteins [18]. This unverified theory is improbable because: a) the fibers in the perifascicular regions do not only stain for MxA but also for all markers of regeneration, as recently confirmed with Mi-2, and for a large number of immune or stressor proteins, as mentioned above; b) does not explain the reduced number of capillaries throughout the fascicle and their relative paucity in the perifascicular regions; c) does not explain the well documented complement activation and MAC deposition on capillaries early in the disease preceding perifascicular atrophy [2,6–10]. Most importantly, and in contrast to MxA theory, the MAC-mediated changes are of direct clinicopathologic relevance because after intercepting complement with IVIg, the patients' strength dramatically improves and the immunopathology resolves [9,19]; d)  $\alpha/\beta$ -interferon-inducible genes lack specificity or uniqueness for DM because they are also overexpressed in the patients' blood not only in DM but also in PM [20]; further  $\alpha/\beta$ -interferon upregulation is ubiquitous in several connective tissue diseases like SLE and Sjögren's syndrome, without an up-to-now therapeutic relevance; and e) in contrast to  $\gamma$ -interferon, there are no functional studies to support toxicity of  $\alpha/\beta$ -interferon to human muscle fibers.

A biologically relevant protein, however discovered by gene arrays, appears to be the KAL-1 adhesion molecule because it is significantly downregulated in patients who improved after therapy [21]. The KAL-1 is upregulated *in vitro* by TGF- $\beta$  and may have a role in inducing fibrosis [15,21].

### Immunobiology of PM and IBM: autoimmunity and viruses

Although IBM is a complex disorder because immune mechanisms co-exist with degeneration as described later, it shares with PM the T-cell-mediated autoimmune process where CD8-positive cytotoxic T-cells attack non-necrotic muscle fibers that express MHC-I antigen [1–4,5<sup>\*</sup>,10]. The T-cells clonally expand *in situ* and persist over time [22,23], as confirmed with laser capture microdissection [24]. Spectratyping has documented the rearrangement of the T-cell receptors as the 'individual fingerprint' of an autoinvasive T-cell, confirming that in PM and IBM distinct clones expand *in situ* after 'seeing' local antigens [25]. The T-cell invasion is facilitated by a local inflammatory environment driven by a range of

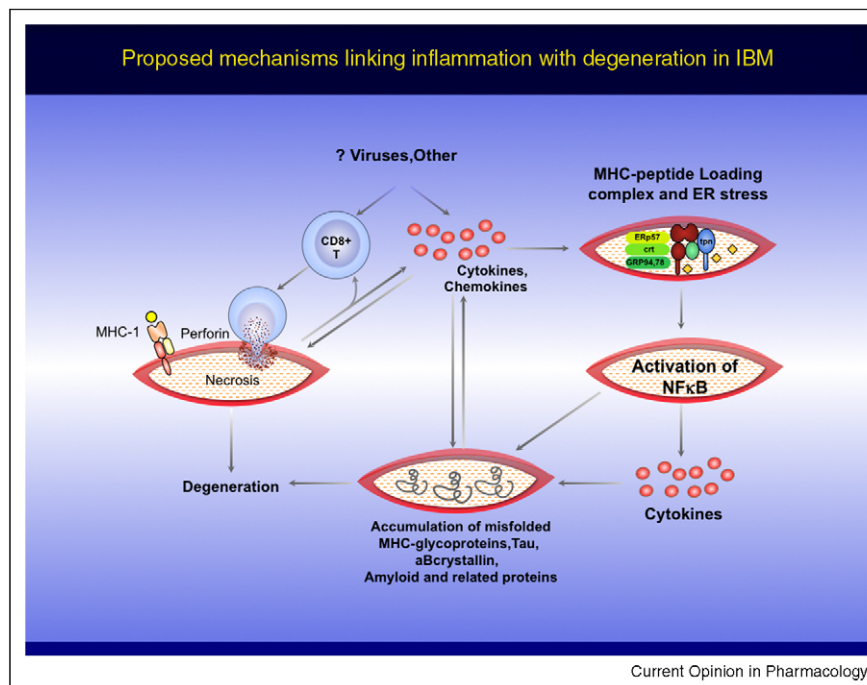
pro-inflammatory cytokines and chemokines that attract immune cells to the muscle.

One of the major observations in the immunobiology of PM and IBM is the ubiquitous overexpression of MHC-I on the surface of muscle fibers [26,27]; this is in contrast to inflammatory dystrophies, the non-immune Necrotizing Myopathies, and other myopathic conditions where MHC-I is absent or limited to the areas of cell infiltrates [10,26,27]. This observation remains fundamental and carries the following diagnostic and immunopathogenic implications. First, the presence of MHC-I/CD8 complex denotes an immune-myositis and should be searched for to secure the diagnosis of PM and IBM. Second, the MHC overexpression alone, can trigger endoplasmic reticulum stress, affect gene expression of structural muscle and stressor proteins, and even trigger inflammation and muscle weakness, at least in the MHC-transgenic mice, an observation of profound significance, as recently reconfirmed [28<sup>\*\*</sup>]. Third, the CD8+ T-cells are primed to receive specific antigenic peptides presented by the MHC-I class antigen and form immunological synapses with the muscle fibers they invade as supported by the upregulation of specific synaptic molecules [29]. In PM and IBM there are also infiltrates of B cells, myeloid dendritic cells and clonally expanded plasma cells, sometimes even forming germinal-like centers [30]. Such lymphoid collections lack specificity for IBM because they are also seen in DM and the targeted tissues of many autoimmune diseases, such as Rheumatoid arthritis, Sjögren syndrome and Multiple Sclerosis; their presence in IBM however strengthens the ongoing immune dysregulation in the muscle microenvironment.

An observation made several years ago [31], but reconfirmed lately because it carries important implications, is that the muscle fibers are not only participating in T-cell recruitment, antigen presentation and co-stimulation [29], but they also contribute to the stimulation of T-cells promoting via cytokines an auto-amplificatory mechanism. Upon cytokine stimulation, muscle fibers *in vivo* can secrete pro-inflammatory cytokines, which facilitate the recruitment of activated T-cells to the muscle and contribute to the self-sustaining nature of endomysial inflammation [32<sup>\*\*</sup>,33]. The muscle fibers therefore are not only the target of the attack but they also generate a pro-inflammatory environment by cytokine secretion. This concept may have implications in our efforts to stop the inflammatory process, as depicted in Figure 1.

It is unclear whether endogenous or exogenous antigens drive the T-cell response. The association of PM and IBM with retroviruses (HIV and HTLV-I in humans and SIV in primates) is however fundamental in understanding potential triggers of muscle autoimmunity [33]. The original observation made several years ago has been now confirmed throughout the world in several dozen patients.

Figure 1



Proposed mechanism on the interplay between inflammation and degeneration in inclusion body myositis (IBM) (from Dalakas MC Ann of Neurology 2008).

Viral or inflammatory triggers lead to clonal expansion of CD8<sup>+</sup> T-cells and T-cell-mediated cytotoxicity via the perforin pathway. The released cytokines upregulate major histocompatibility complex (MHC) class I molecules and increase levels of the MHC-peptide loading complex, because the abundance of generated peptides cannot be conformationally assembled with the MHC to exit the endoplasmic reticulum (ER). As a result, there is an ER stress response, which leads to activation of the transcription factor nuclear factor- $\kappa$ B (NF- $\kappa$ B) and further cytokine release with subsequent accumulation of misfolded MHC glycoproteins, including phosphorylated tau and amyloid-related proteins.

In HIV-positive PM and IBM, the autoinvasive CD8<sup>+</sup> T-cells are clonally expanded and their T-cell receptors contain amino acid residues for specific HLA/viral peptides [34]. The virus is not present within the muscle fiber but only in occasional macrophages around muscle fibers. It appears that in these patients who now live longer and harbor the retrovirus for several years, the chronic persistent viral infection changes the local muscle microenvironment and triggers viral-specific T-cells that reach the muscle fibers. Whether these cells recognize muscle antigens via molecular mimicry remains unclear.

### Necrotizing Myositis (NM): a poorly studied entity

These patients present with high CK, moderate to severe muscle weakness of acute or subacute onset and with histological features of muscle fiber necrosis mediated by macrophages as the main effector cell. There are no T-cell infiltrates or MHC-I expression as seen in PM and IBM; some patients however have antibodies against signal recognition particles (SRP) [35]. The disease is multifactorial. Some patients have cancer or an active viral infection (i.e. HIV); others have been exposed to statins that can induce both, a toxic as well as an auto-

immune Necrotizing Myositis that upregulates MHC-1 and may respond to immunotherapy [36<sup>\*</sup>,37<sup>\*\*</sup>]; others may have a smoldering underlying autoimmune process (we have seen a patient with hyperCKemia up to 8000 who developed lung sarcoidosis and muscle weakness 2 years later); and still others have no other disease or apparent exposure to exogenous agents. Whether NM is triggered by unidentified endogenous or exogenous myotoxic factor(s), or it is an antibody-mediated disease, as suggested by the presence of SRP antibodies, that recruit macrophages via an Antibody-Dependent Cell-Mediated Cytotoxicity (ADCC), remains unclear.

### Degenerative features of IBM: reconciling the role of inflammation and degeneration

IBM is a complex disorder because in addition to immunopathology demonstrates degenerative features evidenced by the presence of rimmed vacuoles, intracellular deposition of Congo-red-positive amyloid and variable accumulation of amyloid-related molecules including APP, amyloid-beta 42, phosphorylated tau detected with antibodies to SMI-31 or the transporter protein p62/SQSTM1, presenilin-1, apolipoprotein E,  $\gamma$ -tubulin, clusterin,  $\alpha$ -synuclein, gelsolin, and a number of

#### 4 Musculoskeletal

oxidative or cell stress-related proteins [38<sup>\*</sup>,39<sup>\*</sup>]. These accumulations recently extended to a number of nuclear-related proteins, such as TDP-43 and VCP [40<sup>\*</sup>,41<sup>\*\*</sup>], are not unique to this disease, as recently demonstrated by Weihl *et al.* [41<sup>\*\*</sup>], because they are also observed in other vacuolar myopathies. What appears unique to IBM however, is the concomitant accumulation of the aforementioned molecules with a strong primary inflammatory response and overexpression of pro-inflammatory mediators and MHC-I antigen [42<sup>\*\*</sup>].

Regardless of whether the primary event is an inflammatory or a protein dysregulation process, recent data suggest a significant interrelationship between inflammation and degeneration [32<sup>\*\*</sup>,42<sup>\*\*</sup>]. Specifically, the inflammatory mediators IFN- $\gamma$  and CXCL-9 correlate at the protein and mRNA level with the expression of APP, a key relevant degenerative marker, and co-localize with APP/ $\beta$ -amyloid proteins. Further, exposure of muscle cells to pro-inflammatory cytokines IL-1 $\beta$  and IFN- $\gamma$  induces an overexpression of APP with subsequent accumulation of  $\beta$ -amyloid. Of interest, in a mouse model of sIBM inflammation induced by the LPS, enhanced the accumulation of tau and  $\beta$ -amyloid [43<sup>\*\*</sup>]. Accordingly, it has been proposed that in IBM a continuous stimulation of inflammatory factors may, after a long period, induce a higher basal expression of APP and an increased sensitivity to *de novo* pro-inflammatory cytokines that triggers a self-perpetuating cycle [5<sup>\*</sup>,32<sup>\*\*</sup>,33,42<sup>\*\*</sup>] (Figure 1).

Another relevant molecule is  $\alpha$ B-crystallin, a heat-shock protein associated with cell stress and  $\beta$ -amyloid clearance, which had been demonstrated in healthy-appearing IBM muscle fibers almost a decade ago [44]. In a recent study, normal-appearing  $\alpha$ B-crystallin-positive fibers were double-positive for APP and MHC-I antigen even before these fibers showed beta-amyloid deposits or other markers of vacuolar degeneration, and even before T-cell invasion [45<sup>\*\*</sup>]. Of relevance, exposure of human myotubes to IL1b and interferon gamma upregulated APP and  $\alpha$ B-crystallin and led to accumulation of  $\beta$ -amyloid. It appears therefore that  $\alpha$ B-crystallin is, along with pro-inflammatory markers, an early event associated with cell stress-response that precedes accumulation of  $\beta$ -amyloid [45<sup>\*\*</sup>]. The following recent cases support the concept that intense inflammation may trigger the typical pathologic features of IBM and present evidence that early initiation of anti-inflammatory therapy may arrest progression to clinical IBM. One was a rapidly progressive patient with DM who had pathological features consistent with IBM, but sustained complete remission with immunotherapy [46<sup>\*\*</sup>]; the second was a patient of ours who presented with rapidly progressive proximal myopathy—clinically suspected to be PM—whose biopsy was consistent with IBM; she too, had complete remission with Prednisone and Mycophenolate. Such cases – albeit anecdotal – are not rare; they have been seen before by others and emphasize the point made above.

#### Disease biomarkers

In Dermatomyositis, the diagnosis is rarely challenged owing to the characteristic skin rash and perifascicular atrophy in the muscle biopsy. By contrast, PM and NM present with proximal muscle weakness of subacute/acute onset without a distinct clinical phenotype; in these patients when toxic, viral, dystrophic, metabolic, and familial processes are excluded, the diagnosis is relied on histology aided by immunopathology. In PM, the presence of T-cells invading non-necrotic fibers scattered in foci along with a ubiquitous expression of MHC-I secures the diagnosis. If vacuoles are seen in this setting, the diagnosis of IBM should be suspected and secured if Congo-red positive deposits and COX-negative fibers are also present [33]. If the patient has the distinct clinical phenotype of IBM and the biopsy does not show vacuoles but only inflammation characterized by MHC-I expression and CD8+ infiltrates, the diagnosis is ‘probable IBM’ or ‘clinical IBM’. Such cases comprise up to 15% of IBM patients [47<sup>\*\*</sup>] and dictate close clinicopathologic correlations to avoid the misdiagnosis of PM; a repeated biopsy from another site may show vacuoles and Congo red-positive deposits. In contrast to PM and sIBM, in NM the infiltrates invading muscle fibers are not CD8+ cells but macrophages, while the MHC-1 expression is not ubiquitous but mostly in the degenerating/necrotic fibers.

Another distal myopathy that may be rarely confused with sIBM, is the sporadic form of ‘myofibrillar myopathy’ [48]. The biopsy in these cases lacks markers of immune inflammation (MHC/CD8) but shows desmin deposits. Because all the molecules accumulated within the IBM muscles are also seen in the other vacuolar myopathies, especially myofibrillar myopathies and hereditary IBM, the two conditions that must be clinically distinguished from sIBM, there is no unique molecule to serve as a specific IBM biomarker. The recently reported 100% specificity of TD-43 for sIBM [49<sup>\*</sup>] is not helpful as TD-43-positivity was also found in myofibrillar myopathies and hereditary IBM; most importantly, these markers have not been tested in patients without vacuoles (probably IBM) that comprise 15% of all IBM and require a diagnostic marker because they are very often misdiagnosed with PM. Similarly, the suggestion that in IBM the pathology starts from the nucleus [49<sup>\*</sup>] lacks neurobiological support and functional studies; the mere immunostaining of nuclear products in the cytoplasm does not disprove the notion that they are probably a consequence of lysosomal degradation and muscle fiber disintegration.

#### Advances in therapeutic strategies: progress in DM and PM and challenges in IBM

Based on experience, but not controlled studies, the majority of patients with PM and DM respond to corticosteroids to some degree and for a period of time. IVIg tested in a controlled study [19] is effective in DM as a second, and at times, first line therapy. IVIg appears also

effective in PM and NM [50\*\*]. Immunosuppressants are used as steroid-sparing agents but their efficacy remains unclear. New agents in the form of monoclonal antibodies or fusion proteins that target cytokines, adhesion molecules, T-cell transduction or transmigration molecules, and B cells or their activation factors are emerging as promising immunotherapeutic drugs relevant to the pathogenesis of myositis, as discussed [50\*\*]. Among them, Rituximab, a B cell-depleting agent, is currently tested in a controlled study. Aggressive DM and NM cases may require combination therapy with intravenous corticosteroids and IVIg.

In contrast to PM and DM, there is currently no effective treatment for sIBM. Prednisone, cyclosporine, azathioprine, methotrexate, total body irradiation, and IFN- $\beta$  failed. Oxandrolone did not help. In some patients, treatment with IVIg induced transient improvement of muscle strength and swallowing, yet the overall study was negative [50\*\*]. Alemtuzumab (Campath), a T-cell-depleting monoclonal antibody, in a small and uncontrolled study, significantly slowed down disease progression for a 6-month period [51\*\*]. Most importantly, this proof-of-principle study showed that depletion of T-cells from the periphery caused reduction of T-cells in the muscle and suppression of some degeneration-associated molecules, based on repeated muscle biopsies. In spite of these changes however, there was no significant improvement in muscle strength highlighting the complexity of IBM.

### Explaining the therapeutic failures in IBM and planning future strategies

The following reasons may explain the lack of treatment efficacy in sIBM:

a) The immunopathogenesis is secondary, so that even a maximal immunosuppression would have a limited effect on the continuing degenerative process. However, as mentioned above and discussed elsewhere [5\*,33], the immune response in IBM is primary and specific and may even precede degeneration; b) therapy is initiated late, when the degenerative cascade has already begun, due to insidious onset and very slow disease progression. After having seen hundreds of IBM patients, we have come to recognize that the disease starts long before the patients develop clinical symptoms, as there is a critical threshold above which weakness is clinically manifested. It is striking that even patients with minimal clinical weakness already exhibit muscle atrophy and extensive pathology in certain muscle groups (histologically or with muscle imaging). The two cases reported above however, highlight the concept that early treatment in patients with histological IBM who have not yet developed the clinical IBM phenotype, may lead to complete remission; c) the production of pro-inflammatory mediators by the muscle fibers themselves may pose a problem in arresting the process because the standard immunosuppressants may not be able to suppress the

factors that trigger the continuous production of cytokines by the muscle fibers themselves [5\*]; d) there are no effective agents to suppress the stressor and  $\beta$ -amyloid-related molecules. The recently observed attenuation of IBM-like myopathy in APP-transgenic mice after immunization with amyloid beta, is of interest [52\*\*], but this model is not similar to human IBM; and e) the correct anti-dysimmune/inflammatory agent has not yet been found as targeted immunotherapy.

Because in IBM, CD8-positive cells invade healthy, non-vacuolated fibers, whereas vacuolated and Congophilic fibers are not invaded by T-cells, we have proposed that the inflammatory and degenerative processes may co-exist from the outset and progress independently [33]. Regardless of which process is the dominant one, an effective treatment may need to concurrently suppress both the degenerative and the inflammatory component from the outset. The noted interaction of the two processes suggests that application of agents with double effect may be therapeutically rewarding. Conducting small but intense bench-to-bedside studies like the one performed with Alemtuzumab [51\*\*] is the way to proceed. The latter study has taught us that suppression of endomysial inflammation may have an effect on some degeneration-associated molecules with resulting short-term clinical stability. This study is important because it suggests that new anti-lymphocyte therapies, if proven safe for long-term therapy, may have an effect not only on inflammatory mediators but also in halting degeneration. It is a new way of thinking with implications beyond inflammatory myopathies. As the industry is generating new such agents, we should take advantage if there are no long-term safety concerns. The same applies to agents suppressing the 'degenerative' molecules. In Alzheimer's disease, where these same molecules are abundant, no therapy has been effective. In support of the neuroinflammatory concept however, the main drug that shows some promise in Alzheimer's disease is IVIG [53].

### References and recommended reading

Papers of particular interest, published within the annual period of review, have been highlighted as:

- of special interest
- of outstanding interest

1. Dalakas MC: **Polymyositis, dermatomyositis and inclusion-body myositis**. *N Engl J Med* 1991, **325**:1487-1498.
2. Engel AG, Hohlfeld R: In *Myology*, edn 3. Edited by Engel AG, Franzini-Armstrong C. New York: McGraw-Hill; 2004:1321-1366.
3. Mastaglia FL, Phillips BA: **Idiopathic inflammatory myopathies: epidemiology, classification and diagnostic criteria**. *Rheum Dis Clin North Am* 2002, **28**:723-741.
4. Dalakas MC, Hohlfeld R: **Polymyositis and dermatomyositis**. *Lancet* 2003, **362**:971-982.
5. Schmidt J, Dalakas MC: **Pathomechanisms of Inflammatory Myopathies: Recent Advances and Implications for Diagnosis and Therapies**. *Exp Opin Med Diagnos*. In press. doi:10.1517/17530051003713499.

## 6 Musculoskeletal

A nice review with recent updates.

6. de Visser M, Emslie-Smith AM, Engel AG: **Early ultrastructural alterations in adult dermatomyositis. Capillary abnormalities precede other structural changes in muscle.** *J Neurol Sci* 1989, **94**:181-192.
7. Kissel JT, Mendell JR, Rammohan KW: **Microvascular deposition of complement membrane attack complex in dermatomyositis.** *N Engl J Med* 1986, **314**:329-334.
8. Emslie-Smith AM, Engel AG: **Microvascular changes in early and advanced dermatomyositis: a quantitative study.** *Ann Neurol* 1990, **27**:343-356.
9. Basta M, Dalakas MC: **High-dose intravenous immunoglobulin exerts its beneficial effect in patients with dermatomyositis by blocking endomysial deposition of activated complement fragments.** *J Clin Invest* 1994, **94**:1729-1735.
10. Dalakas MC: **Mechanisms of disease: signaling pathways and immunobiology of inflammatory myopathies.** *Nat Clin Pract Rheumatol* 2006, **2**:219-227.
11. Greenberg SA, Pinkus JL, Pinkus GS, Bureson T, Sanoudou D, Tawil R, Barohn RJ, Saperstein DS, Briemberg HR, Ericsson M *et al.*: **Interferon-alpha/beta-mediated innate immune mechanisms in dermatomyositis.** *Ann Neurol* 2005, **57**:664-678.
12. Tezak Z, Hoffman EP, Lutz JL, Fedczyna TO, Stephan D, Bremer EG, Krasnoselska-Riz I, Kumar A, Pachman LM: **Gene expression profiling in DQA1\*0501+ children with untreated dermatomyositis: a novel model of pathogenesis.** *J Immunol* 2002, **168**:4154-4163.
13. López De Padilla CM, Vallejo AN, Lacomis D, McNallan K, Reed AM: **Extranodal lymphoid microstructures in inflamed muscle and disease severity of new-onset juvenile dermatomyositis.** *Arthritis Rheum* 2009, **60**:1160-1172.  
Lymphoid aggregates with a germinal center-like formation were nicely demonstrated in DM accompanied by a thoughtful discussion on their significance in possible antibody production.
14. Bilgic H, Ytterberg SR, Amin S, McNallan KT, Wilson JC, Koeuth T, Ellingson S, Newman B, Bauer JW, Peterson EJ *et al.*: **Interleukin-6 and type I interferon-regulated genes and chemokines mark disease activity in dermatomyositis.** *Arthritis Rheum* 2009, **60**:3436-3446.  
IL-6 and type I interferon genes may be candidate disease biomarkers in DM. The high IL-6 may generate new targeted therapeutic strategies.
15. Amemiya K, Semino-Mora C, Granger RP, Dalakas MC: **Downregulation of TGF-beta1 mRNA and protein in the muscles of patients with inflammatory myopathies after treatment with high-dose intravenous immunoglobulin.** *Clin Immunol* 2000, **94**:99-104.
16. Gallardo E, de A, Illa I: **Cathepsins are upregulated by IFN-gamma/STAT1 in human muscle culture: a possible active factor in dermatomyositis.** *J Neuropathol Exp Neurol* 2001, **60**:847-855.
17. Mammen AL, Casciola-Rosen LA, Hall JC, Christopher-Stine L, Corse AM, Rosen A: **Expression of the dermatomyositis autoantigen Mi-2 in regenerating muscle.** *Arthritis Rheum* 2009, **60**:3784-3793.  
An important study, demonstrating that the autoantibody against chromatin remodeler Mi-2, which is present in some DM patients, is strongly immunolocalized in the perifascicular fibers but also in the regenerating muscle *in vivo*. The study confirms that the perifascicularly atrophic fibers are indeed regenerating and that Mi-2 may play a role in myofiber stability during the regenerating process.
18. Greenberg SA: **Proposed immunologic models of the inflammatory myopathies and potential therapeutic implications.** *Neurology* 2007, **69**:2008-2019.
19. Dalakas MC, Dambrosia JM, Soueidan SA, Stein DP, Otero C, Dinsmore ST, McCrosky S: **A controlled trial of high-dose intravenous immunoglobulin infusions as treatment for dermatomyositis.** *N Engl J Med* 1993, **329**:1993-2000.
20. Walsh RJ, Kong SW, Yao Y, Jallal B, Kiener PA, Pinkus JL, Beggs AH, Amato AA, Greenberg SA: **Type I interferon-inducible gene expression in blood is present and reflects disease**

**activity in dermatomyositis and polymyositis.** *Arthritis Rheum* 2007, **56**:3784-3792.

21. Raju R, Dalakas MC: **Gene expression profile in the muscles of patients with inflammatory myopathies: effect of therapy with IVIg and biological validation of clinically relevant genes.** *Brain* 2005, **128**:1887-1896.
22. Benveniste O, Herson S, Salomon B, Dimitri D, Trébeden-Nègre H, Jean L, Bon-Durand V, Antonelli D, Klatzmann D, Boyer O: **Long-term persistence of clonally expanded T cells in patients with polymyositis.** *Ann Neurol* 2004, **56**:867-872.
23. Amemiya K, Granger RP, Dalakas MC: **Clonal restriction of T-cell receptor expression by infiltrating lymphocytes in inclusion body myositis persists over time. Studies in repeated muscle biopsies.** *Brain* 2000, **123**:2030-2093.
24. Hofbauer M, Wiesener S, Babbe H, Roers A, Wekerle H, Dornmair K, Hohlfeld R, Goebels N: **Clonal tracking of autoaggressive T cells in polymyositis by combining laser microdissection, single-cell PCR, and CDR3-spectratype analysis.** *Proc Natl Acad Sci USA* 2003, **100**:4090-4095.
25. Salajegheh M, Rakocevic G, Raju R, Shatunov A, Goldfarb LG, Dalakas MC: **T cell receptor profiling in muscle and blood lymphocytes in sporadic inclusion body myositis.** *Neurology* 2007, **69**:1672-1679.
26. Karpati G, Pouliot Y, Carpenter S: **Expression of immunoreactive major histocompatibility complex products in human skeletal muscles.** *Ann Neurol* 1988, **23**:64-72.
27. Emslie-Smith AM, Arahata K, Engel AG: **Major histocompatibility complex class I antigen expression, immunolocalization of interferon subtypes, and T cell-mediated cytotoxicity in myopathies.** *Hum Pathol* 1989, **20**:224-231.
28. Li CK, Knopp P, Moncrieffe H, Singh B, Shah S, Nagaraju K, Varsani H, Gao B, Wedderburn LR: **Overexpression of MHC class I heavy chain protein in young skeletal muscle leads to severe myositis: implications for juvenile myositis.** *Am J Pathol* 2009, **175**:1030-1040.  
An important study confirming previous work by the same group that overexpression of MHC-1 in young animals leads to a more severe clinical phenotype by upregulating genes involved in ER stress and the ubiquitin-proteasome system.
29. Wiendl H, Hohlfeld R, Kieseier BC: **Immunobiology of muscle: advances in understanding an immunological microenvironment.** *Trends Immunol* 2005, **26**:373-380.
30. Greenberg SA, Pinkus GS, Amato AA, Pinkus JL: **Myeloid dendritic cells in inclusion-body myositis and polymyositis.** *Muscle Nerve* 2007, **35**:17-23.
31. Hohlfeld R, Engel AG: **Coculture with autologous myotubes of cytotoxic T cells isolated from muscle in inflammatory myopathies.** *Ann Neurol* 1991, **29**:498-507.
32. Schmidt J, Barthel K, Wrede A, Salajegheh M, Bähr M, Dalakas MC: **Interrelation of inflammation and APP in sIBM: IL-1 beta induces accumulation of beta-amyloid in skeletal muscle.** *Brain* 2008, **131**:1228-4050.  
Seminal study that demonstrates the interrelationship between inflammation and degeneration. Functional studies confirm that exposure of muscle cells to pro-inflammatory cytokines induces an overexpression of APP with subsequent accumulation of amyloid aggregates
33. Dalakas MC: **Sporadic inclusion body myositis: diagnosis, pathogenesis and therapeutic strategies.** *Nat Clin Pract Neurol* 2006, **2**:437-447.
34. Dalakas MC, Rakocevic G, Shatunov A, Goldfarb L, Salajegheh M: **IBM with HIV infection: 4 new cases with clonal expansion of viral-specific T cells.** *Ann Neurol* 2007, **61**:466-475.
35. Hengstman GJ, Vree Egberts WT, Seelig HP, Lundberg IE, Moutsopoulos HM, Doria A, Mosca M, Vencovsky J, van Venrooij WJ, van Engelen BG: **Clinical characteristics of patients with myositis and autoantibodies to different fragments of the Mi-2 beta antigen.** *Ann Rheum Dis* 2006, **65**:242-245.
36. Dalakas MC: **Toxic and drug-induced myopathies.** *J Neurol Neurosurg Psychiatry* 2009, **80**:832-838.

The various drugs, especially statins, that trigger myopathies are reviewed and a differential diagnosis is provided.

37. Needham M, Fabian V, Knezevic W, Panegyres P, Zilko P, Mastaglia FL: **Progressive myopathy with upregulation of MHC-I associated with statin therapy.** *Neuromuscul Disord* 2007, **17**:194-200.
- An important study demonstrating that statins can induce an MHC-I upregulated autoimmune myopathy responding to immunotherapies.
38. Askanas V, Engel WK, Nogalska A: **Inclusion body myositis: a degenerative muscle disease associated with intra-muscle fiber multi-protein aggregates, proteasome inhibition, endoplasmic reticulum stress and decreased lysosomal degradation.** *Brain Pathol* 2009, **19**:493-506.
- A nice review of the various proteins accumulated in the muscle fibers of IBM patients. Arguments favoring the degenerative process are provided.
39. Nogalska A, Terracciano C, D'Agostino C, King Engel W, Askanas V: **p62/SQSTM1 is overexpressed and prominently accumulated in inclusions of sporadic inclusion-body myositis muscle fibers, and can help differentiating it from polymyositis and dermatomyositis.** *Acta Neuropathol* 2009, **118**:407-413.
- The protein p62, a shuttle protein transporting ubiquitinated proteins, stained the p-tau inclusions in sIBM but not DM or PM.
40. Salajegheh M, Pinkus JL, Nazareno R, Amato AA, Parker KC: **Greenberg SA Nature of "Tau" immunoreactivity in normal myonuclei and inclusion body myositis.** *Muscle Nerve* 2009, **40**:520-528.
- Antibodies against tau were found to stain even normal myonuclei.
41. Wehl CC, Temiz P, Miller SE, Watts G, Smith C, Forman M, Hanson PI, Kimonis V, Pestronk A: **TDP-43 accumulation in inclusion body myopathy muscle suggests a common pathogenic mechanism with frontotemporal dementia.** *J Neurol Neurosurg Psychiatry* 2008, **79**:1186-1189.
- Nice study demonstrating TD43 in the muscle of patients with IBM but also myofibrillar myopathies and hIBM.
42. Dalakas MC: **Interplay between inflammation and degeneration: using inclusion body myositis to study neuroinflammation.** *Ann Neurol* 2008, **64**:1-3.
- A critical Editorial emphasizes the new concept of neuroinflammation in IBM based on the cross-talk between inflammatory and degenerative molecules.
43. Kitazawa M, Trinh DN, LaFerla FM: **Inflammation induces tau pathology in inclusion body myositis model via glycogen synthase kinase-3beta.** *Ann Neurol* 2008, **64**:15-24.
- Important study confirming that inflammation in the IBM model can induce degeneration.
44. Banwell BL, Engel AG: **alpha B-crystallin immunolocalization yields new insights into inclusion body myositis.** *Neurology* 2000, **54**:1033-1041.
45. Muth IE, Barthel K, Bähr M, Dalakas MC, Schmidt J: **Proinflammatory cell stress in sporadic inclusion body myositis muscle: overexpression of alphaB-crystallin is associated with amyloid precursor protein and accumulation of beta-amyloid.** *J Neurol Neurosurg Psychiatry* 2009, **80**:1344-1349.
- The authors convincingly demonstrate that  $\alpha$ B-crystallin is, along with pro-inflammatory markers, an early event associated with cell stress-response that precedes accumulation of  $\beta$ -amyloid.
46. Layzer R, Lee HS, Iverson D, Margeta M: **Dermatomyositis with inclusion body myositis pathology.** *Muscle Nerve* 2009, **40**:469-471.
- Single case report but of significance. It presents a patient with DM with pathologic features of IBM supporting the concept that intense inflammation may trigger the typical pathologic features of IBM and that early initiation of anti-inflammatory therapy may arrest progression to clinical IBM.
47. Chahin N, Engel AG: **Correlation of muscle biopsy, clinical course, and outcome in PM and sporadic IBM.** *Neurology* 2008, **70**:418-424.
- Important study introducing the concept of PM/IBM in up to 15% of patients with clinical features of IBM who did not have vacuoles or amyloid deposits.
48. Goldfarb LG, Dalakas MC: **Tragedy in a heartbeat: malfunctioning desmin causes skeletal and cardiac muscle disease.** *J Clin Invest* 2009, **119**:1806-1813.
49. Salajegheh M, Pinkus JL, Taylor JP, Amato AA, Nazareno R, Baloh RH, Greenberg SA: **Sarcoplasmic redistribution of nuclear TDP-43 in inclusion body myositis.** *Muscle Nerve* 2009, **40**:19-31.
- The presence of TD43 is demonstrated in IBM muscle. In contrast to the authors' conclusions, the significance in disease mechanisms and biomarkers is unclear.
50. Dalakas MC: **Advances in the treatment of Myositis.** *Nat Rev Rheumatol* 2010, **6**, 129-137.
- An up to date critical review of current and future therapies in all forms of myositis.
51. Dalakas MC, Rakocevic G, Schmidt J, Salajegheh M, McElroy B, Harris-Love MO, Shrader JA, Levy EW, Dambrosia J, Kampen RL et al.: **Effect of Alemtuzumab (CAMPATH 1-H) in patients with inclusion-body myositis.** *Brain* 2009, **132**:1536-1544.
- An excellent clinicopathologic proof-of-principle study demonstrating that depletion of T-cells from the periphery results in suppression of endomysial inflammation and some degeneration-associated molecules along with short-term clinical stability. The study, although small and uncontrolled, is important because anti-lymphocyte therapies may have an effect not only on inflammatory mediators but also in halting degeneration.
52. Kitazawa M, Vasilevko V, Cribbs DH, LaFerla FM: **Immunization with amyloid-beta attenuates inclusion body myositis-like myopathy and motor impairment in a transgenic mouse model.** *J Neurosci* 2009, **29**:6132-6141.
- In APP transgenic mice with IBM-like pathology, immunization with beta amyloid, attenuated the morphology, and resulted in motor improvement. The relevance to human IBM is unclear.
53. Hughes RAC, Dalakas MC, Cornblath DR, Latov N, Weksler ME, Relkin N: **Clinical applications of Intravenous immunoglobulins in neurology.** *Clin Exp Immunol* 2009, **158**(Suppl. 1):34-42.