

Dysphagia: 101

Todd D Levine, MD

Phoenix Neurological Associates
University of Arizona

Symptoms of Dysphagia

- Coughing/ Choking
 - Can occur with solids or liquids.
 - More severe if symptoms are present with liquids
 - Can also occur spontaneously associated with one's own saliva
- Frequent Throat Clearing
- Wet Vocal Quality

Symptoms of Dysphagia

- Drooling
- Eating meals more slowly
- Weight loss. Considered excess weight loss if:
 - $>2\%$ of body weight in 1 week
 - $> 5\%$ in 1 month
 - $>7.5\%$ in 3 months
 - $>10\%$ in 6 months

Causes of Dysphagia

- Head and Neck Surgery 36%
- Stroke 29%
- Closed Head Injury 7%
- Spinal Cord Injury 6%
- Neuromuscular Disease 6%
 - As many as 30% of myositis pts develop dysphagia
- Vocal Cord Problem 4%
- Zenker's Diverticulum 2%
- Anxiety 2-5%

Dysphagia and Myositis

- Can occur in all forms of myositis but most common in IBM and childhood DM.
- Can be the presenting symptom for some patients as well
- In PM and DM response to therapy is not always the same for dysphagia as it is for other muscles.

Evaluation of Dysphagia

- If someone has a known diagnosis of myositis then the neurologist or rheumatologist should screen for the symptoms and will initiate evaluation.
- If dysphagia is the presenting symptom then often seen by Primary Care or GI before Neuro or Rheum.
- Easy at home evaluation is to drink a glass of water and then speak. If it sounds wet then this should be evaluated.

Anatomy of Dysphagia: Oropharynx

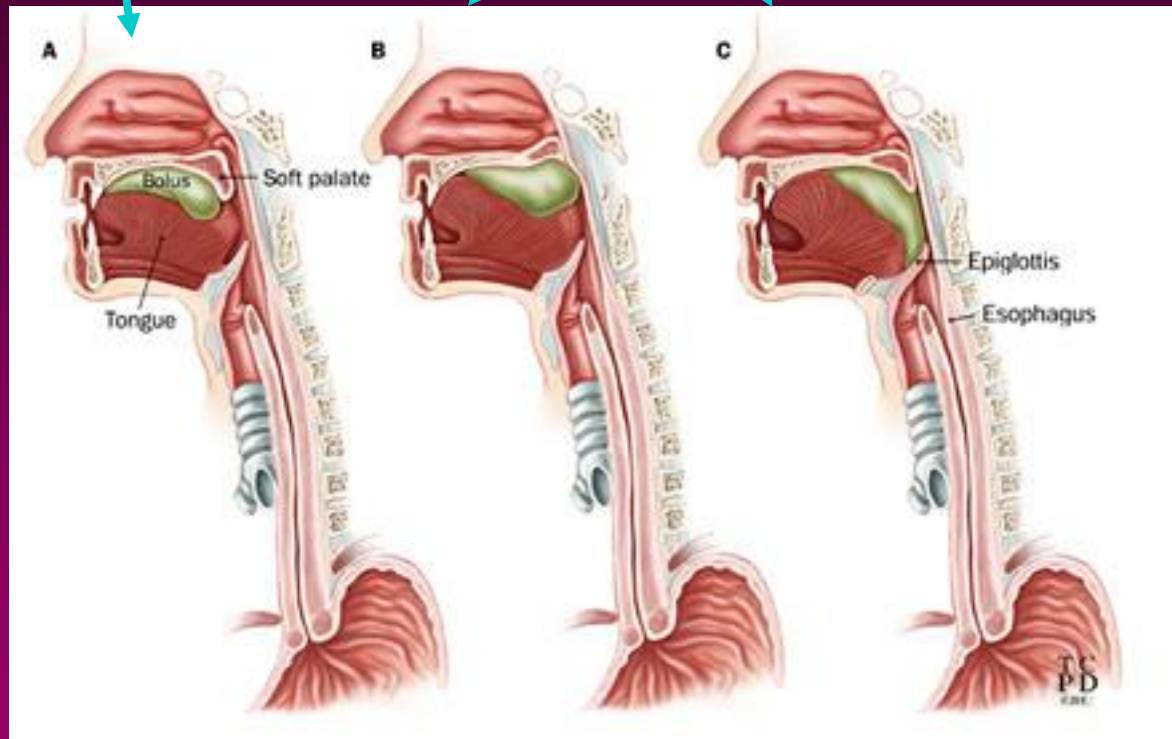
- Swallowing is one of the most complex automatic behaviors we do. So it is expected that many diseases can affect the swallow mechanism.
- Oropharynx
 - Teeth
 - Salivary glands
 - Tongue

Physiology of Swallowing

- Oral Phase
- Pharyngeal Phase
- Esophageal Phase

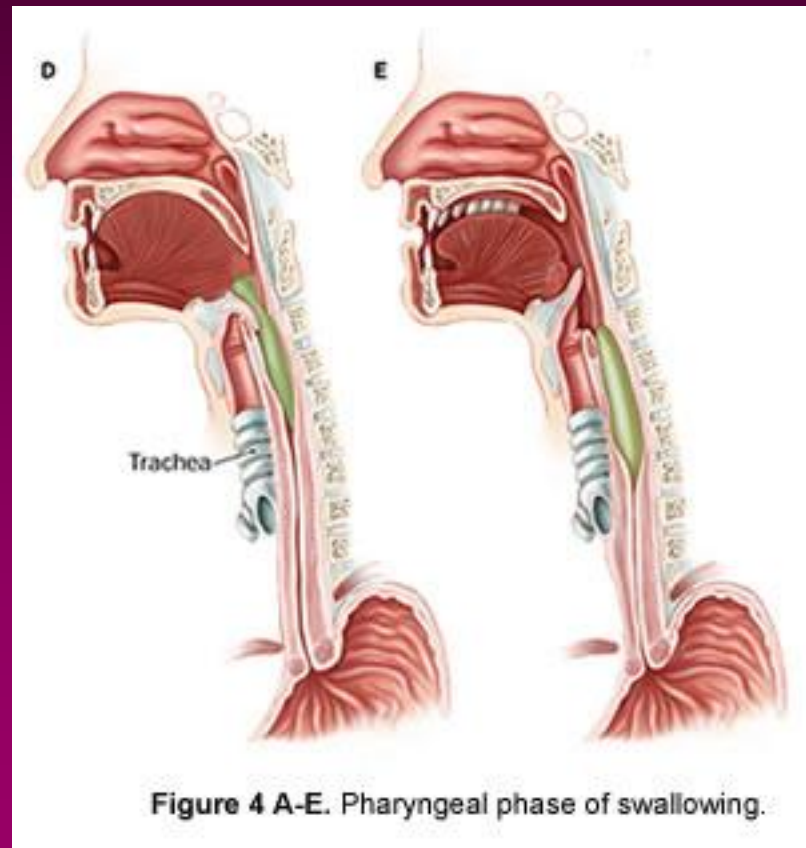
Physiology of Swallowing:

Oral Pharyngeal Phase



Physiology of Swallowing

Pharyngeal and Esophageal Phase:



Oral Phase

- Begins with oral preparation of bolus
 - Liquid:
 - Lips sealed->held briefly between hard palate and tongue->one or more complete swallows
 - Soft Foods:
 - held between hard palate and tongue
 - lateralized for mastication if needed
 - if falls apart, acts like liquid
 - if thick precise tongue control for compression into the hypopharynx.

Oral Phase

- Begins with oral preparation of bolus
 - Solid Foods:
 - require mastication:
 - temperature, pressure, texture=> 5th cranial n.
 - reflexive relaxation of masseter and temporalis
 - stretch reflex=>rebound closure=>repeat cycle.
 - Salivation
 - Necessary to have moist mouth. Certain diseases like Sjogren's syndrome can cause dysphagia because of lack of saliva

Oral Phase

- Tongue elevates
- Propels food toward oropharynx
- Palatopharyngeal folds contract forming medial slit at base of tongue,
- Nasopharyngeal port blocked by levator and tensor palatine muscles.

Pharyngeal Phase

- Medullary reticular formation in the brain controls this phase (swallowing center)
- complex series of motor events propelling bolus through pharynx, away from airway into esophagus

Pharyngeal Phase

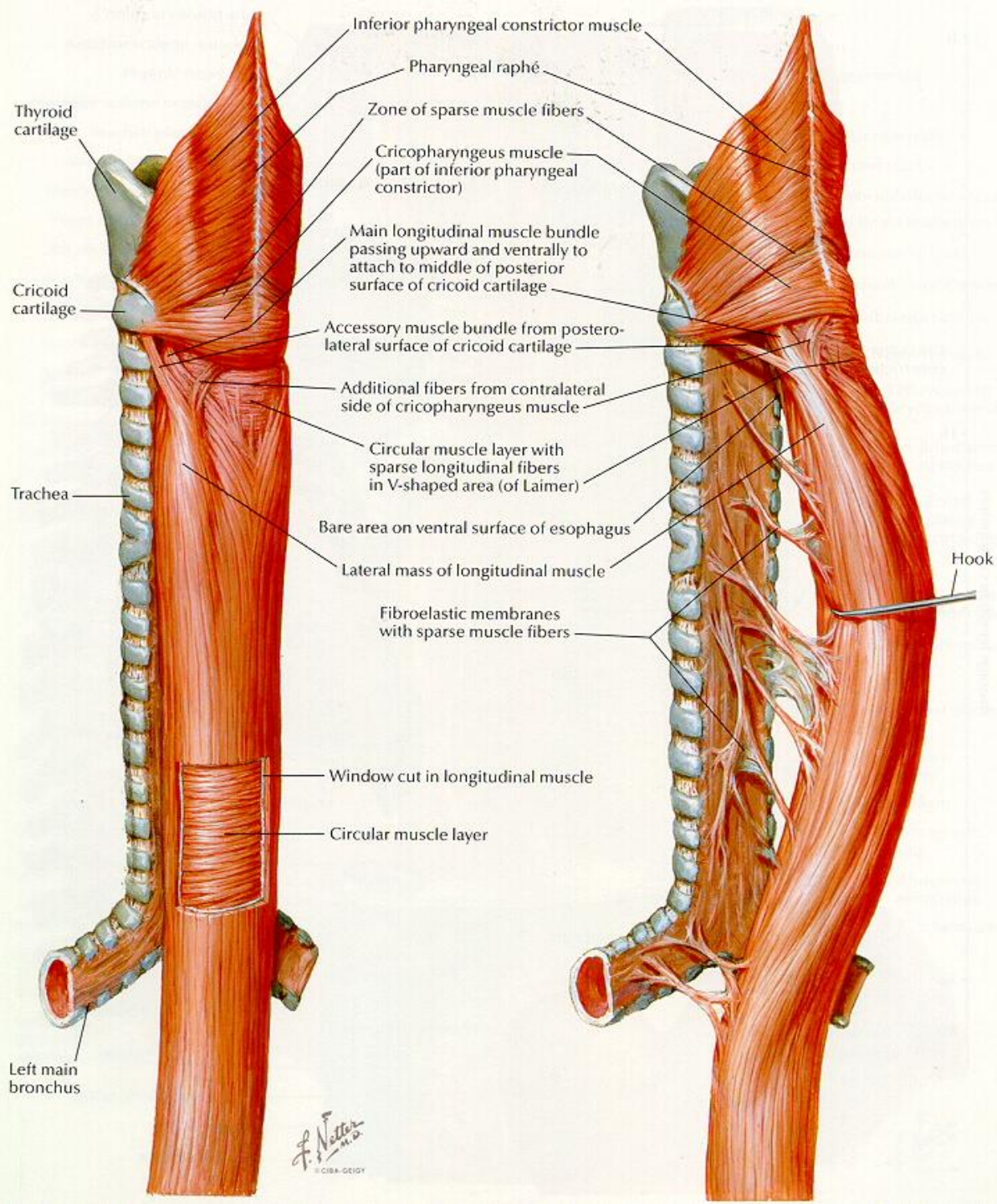
- Posterior tongue movement and a pharyngeal constricting wave
- Laryngeal elevation and tilting with epiglottis turning under and vocal cords closing
- Relaxation of cricopharyngeal muscle (upper esophageal sphincter)
- Food enters into esophagus

Pharyngeal Phase

- Pharyngeal constricting wave continues throughout esophagus as primary peristaltic wave.
- Secondary peristaltic wave arise locally to propel bolus through Lower esophageal sphincter.

Anatomy of Dysphagia: Esophagus

- Pharyngeal constrictors
 - Propel food downward
- Cricopharyngeal sphincter
- Body of esophagus
 - upper 1/2 skeletal muscle
 - lower 1/2 smooth muscle
- Lower esophageal sphincter



Strictures / Caustic Ingestion

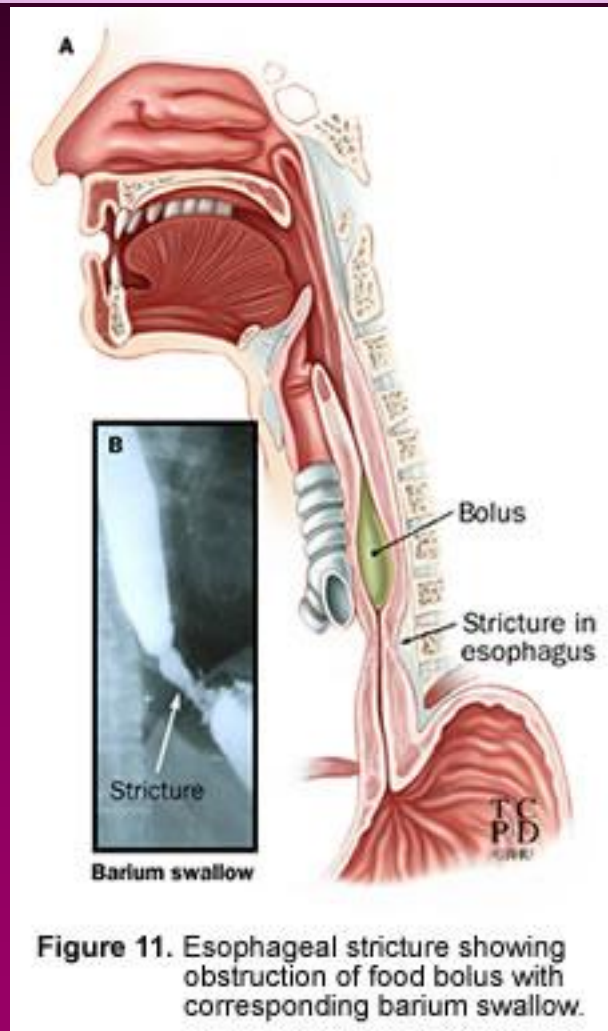
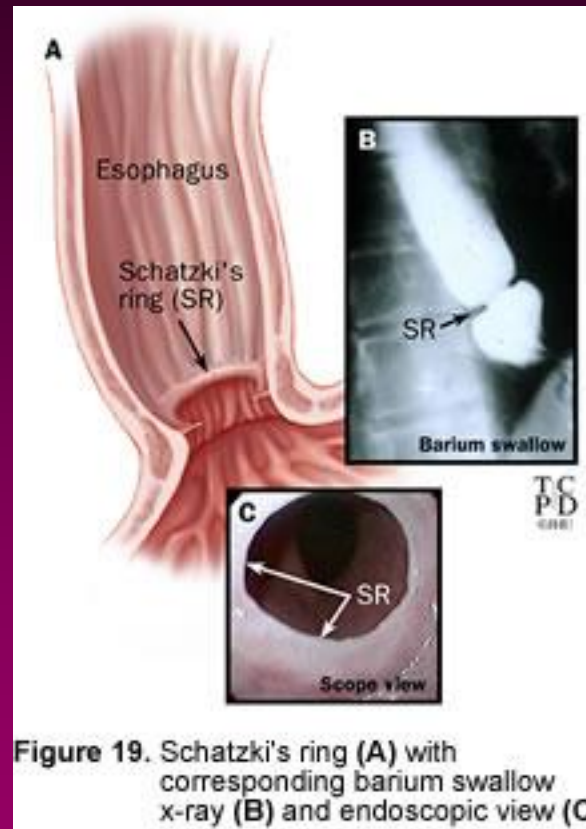
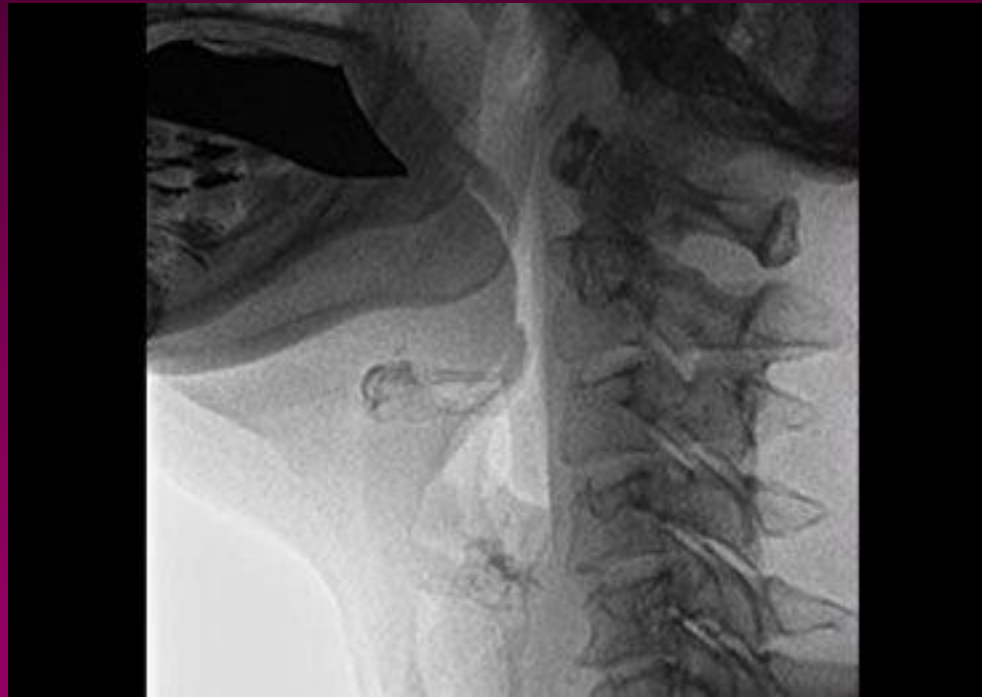

Figure 11. Esophageal stricture showing obstruction of food bolus with corresponding barium swallow.

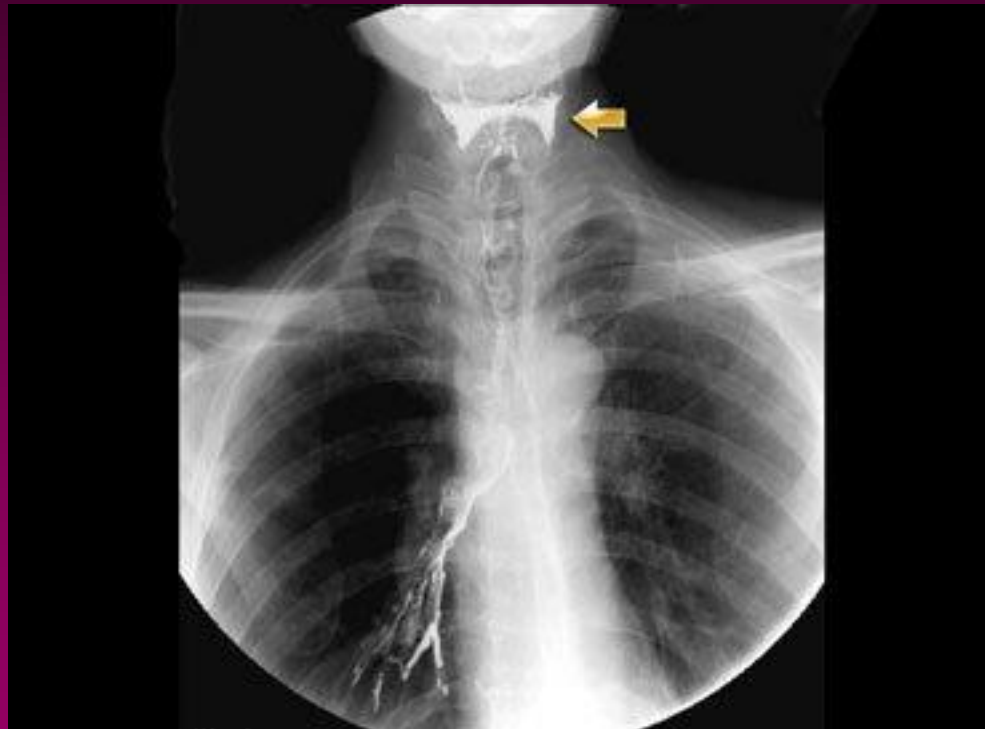Esophageal Webs and Rings



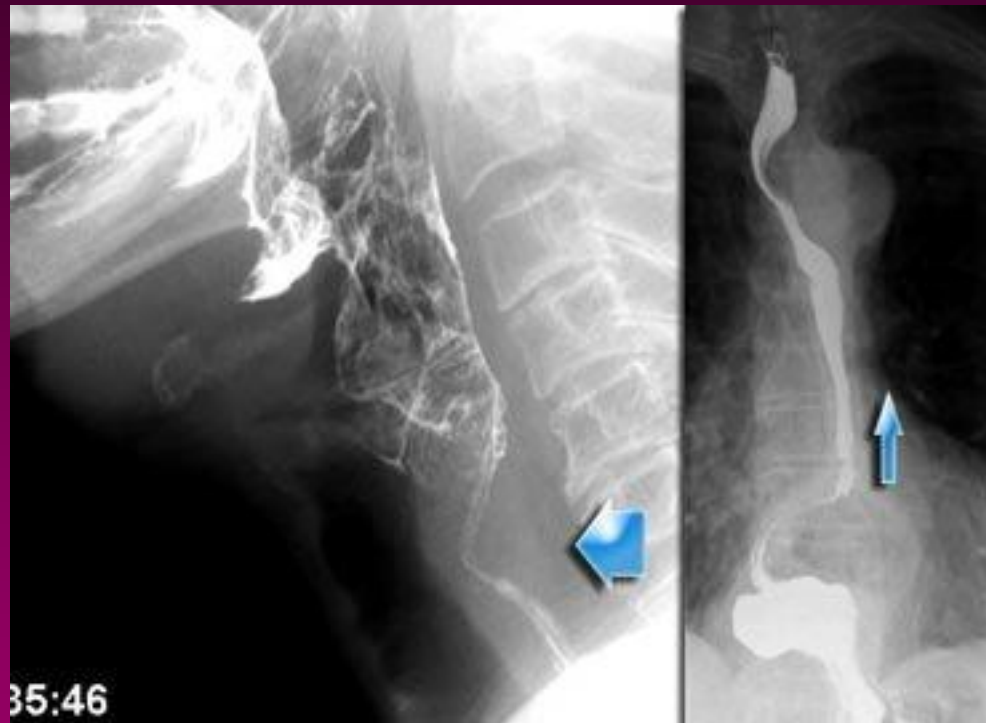Lateral view of MBS



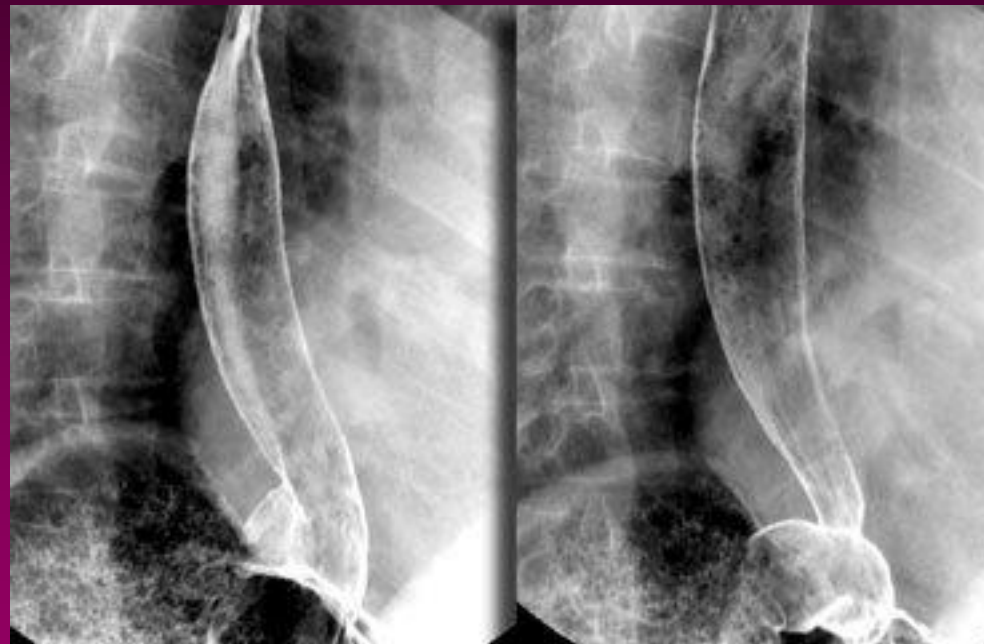Stasis in Pyriform sinus



Cricopharyngeal hypertrophy

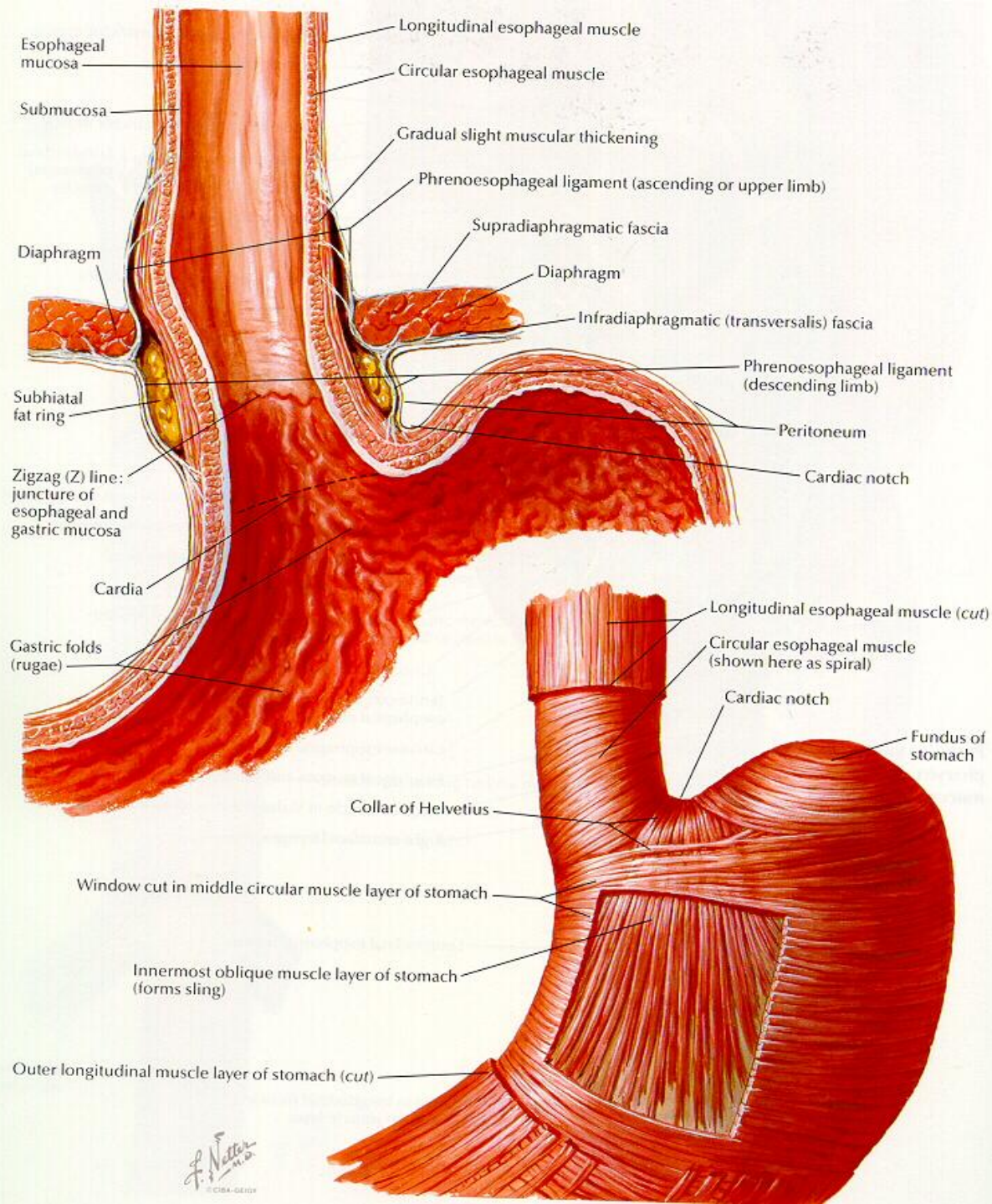


Views of the GE Junction

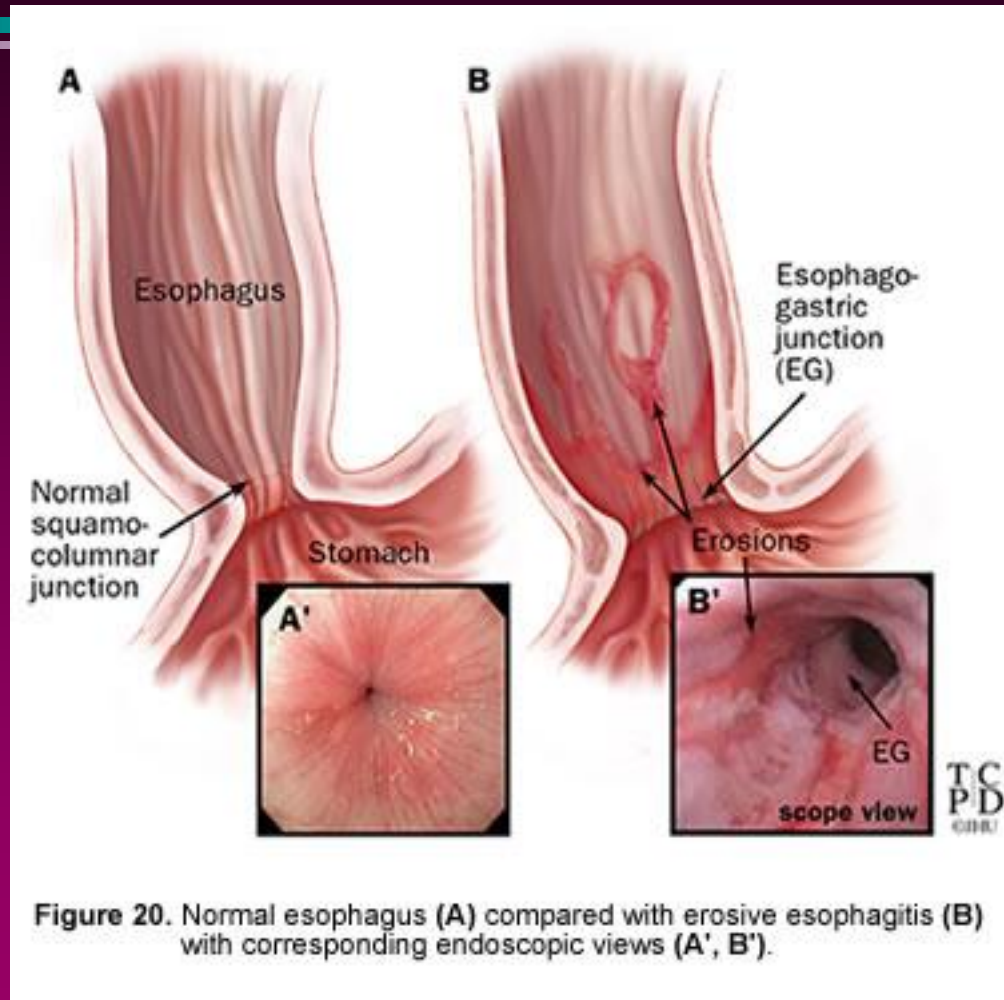


Anatomy of Dysphagia: Stomach

- Reservoir
- Initiates digestion
 - pepsin
 - HCl
 - intrinsic factor
 - mucous
- Peristalsis



Gastroesophageal Reflux Disease



Evaluation of Swallowing

- Bedside Evaluation
 - Easy, detects significant problems
 - Wet voice test with drinks of water
- FEES
 - Defines anatomy, looks for aspiration
- MBS
 - Detects aspiration, defines anatomy, also defines how bad, and the etiology.

Aspiration Pneumonia Risk Factors

Host Factors

- Neurologic

- Advance age
- laryngeal n. damage
- Acute stroke
- Neuromuscular Diseases
- Parkinson's Dz
- General anesthesia
- Alcoholism

- Mechanical

- Obesity
- Head & neck surgery
- Bowel obstruction
- Abdominal surgery
- Pregnancy
- Endotracheal intubation
- Tracheostomy

Dysphagia and Aspiration

- Aspiration pneumonia
 - frequently life threatening
 - common in hospitalized patients
 - bacteremia, sepsis, respiratory arrest & death
 - associated with swallowing dysfunction, upper GI d/o due to central and peripheral neurologic dz, mechanical and obstructive diseases.

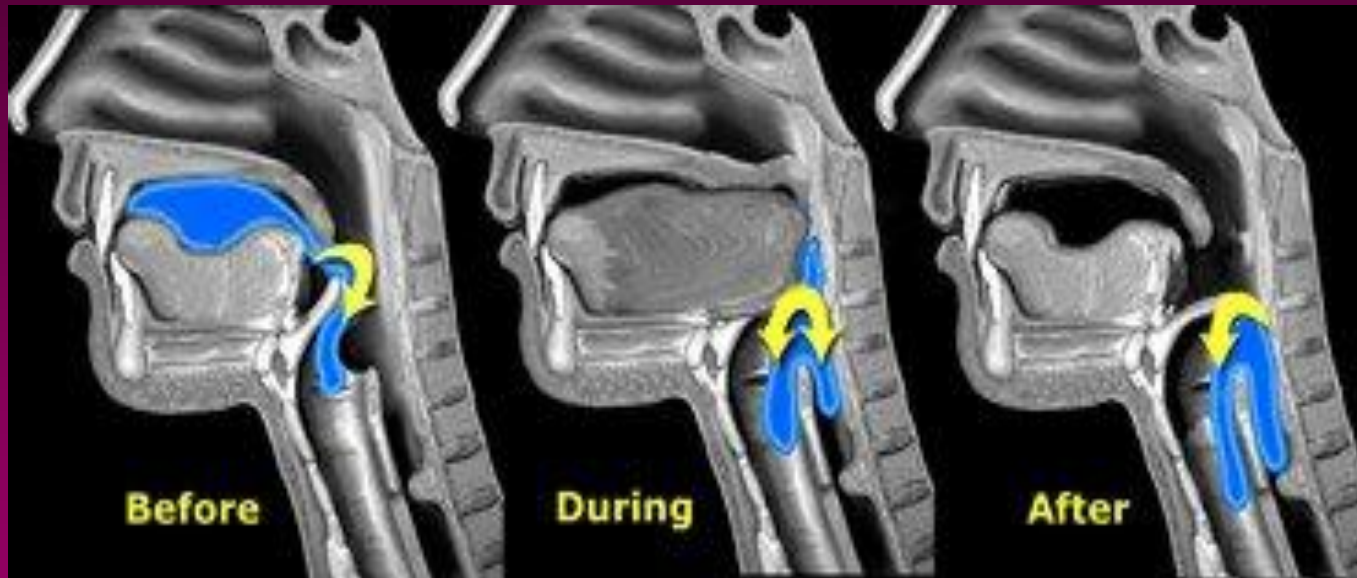
Dysphagia and Aspiration

- Spectrum of aspiration
 - laryngeal penetration to frank aspiration pneumonia progressing to end organ hypoxia
 - not all aspiration leads to pneumonia:
 - half of normal subjects aspirate during sleep

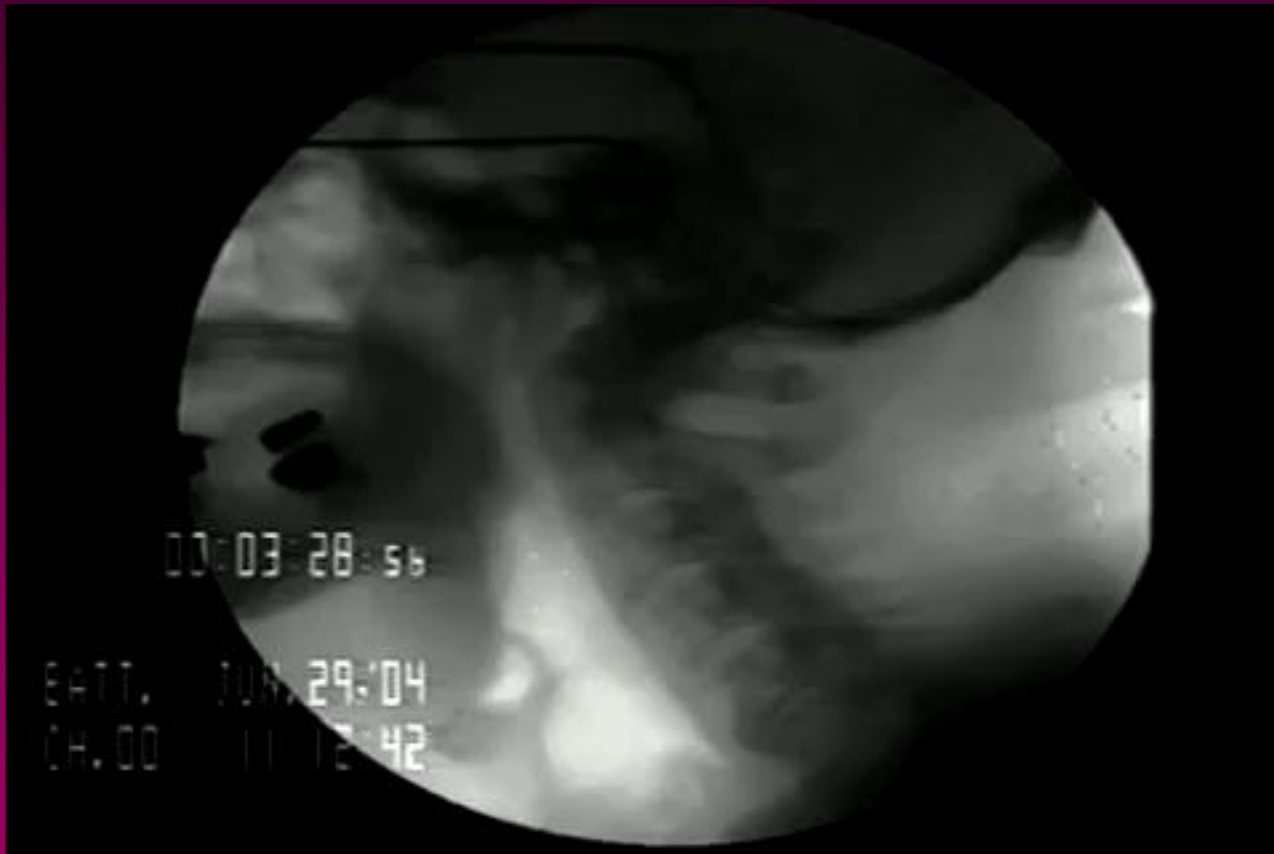Diagnosis and Treatment of Dysphagia

Type	Signs	Causes	Treatment
Oral Prep	Leakage	Sensory Loss	Place food posteriorly
Oral	Buccal Pocketing	Facial weakness	Exercises
Oral	Chewing labored	Dentition, Cognition	Modify food texture
Oral	Leakage	Lingual weakness	Chin tuck, Food texture
Pharyngeal	Delayed swallow	Vagus nerve	Thermal stim
Pharyngeal	Multiple swallow	Weak muscles	Alternate liquids and solids
Pharyngeal	Cough/clear	Aspiration	Food texture
Pharyngeal	Change in voice	Penetration to vocal cords	NPO
Esophageal	Delayed aspiration	Reflex, stricture	Meds GI Doc

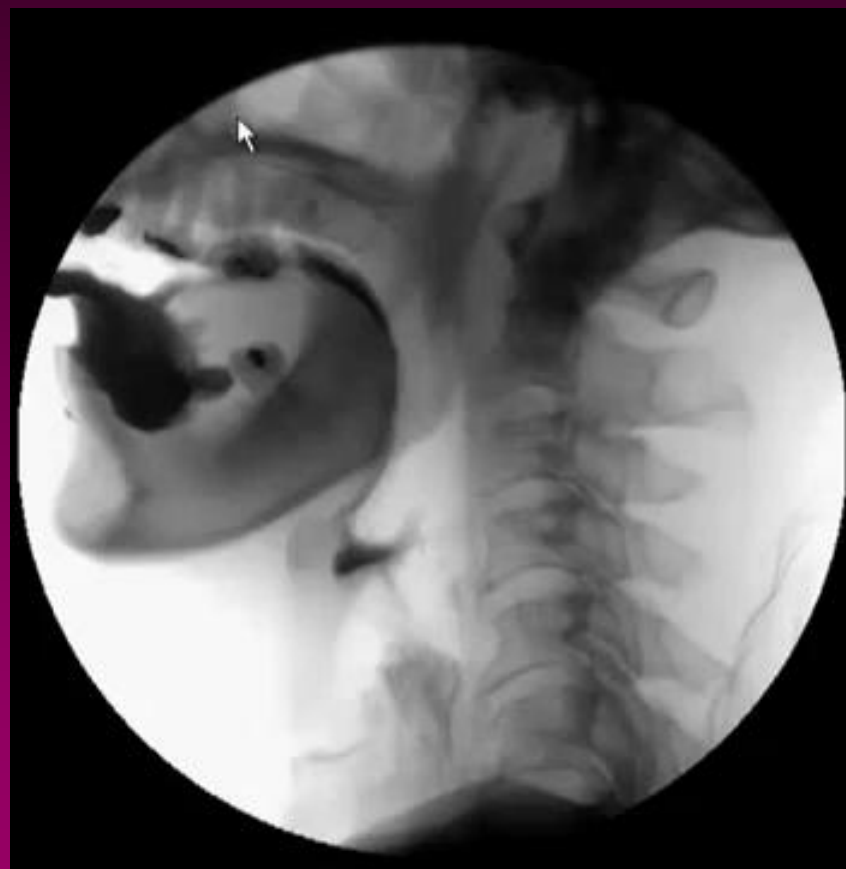Aspiration



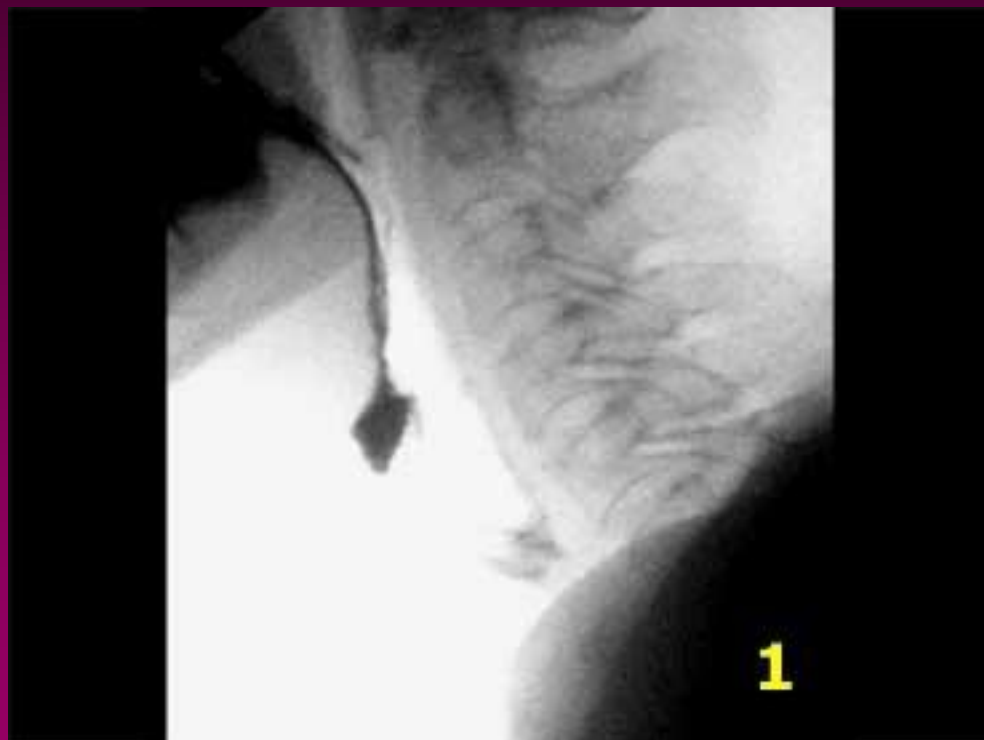Aspiration



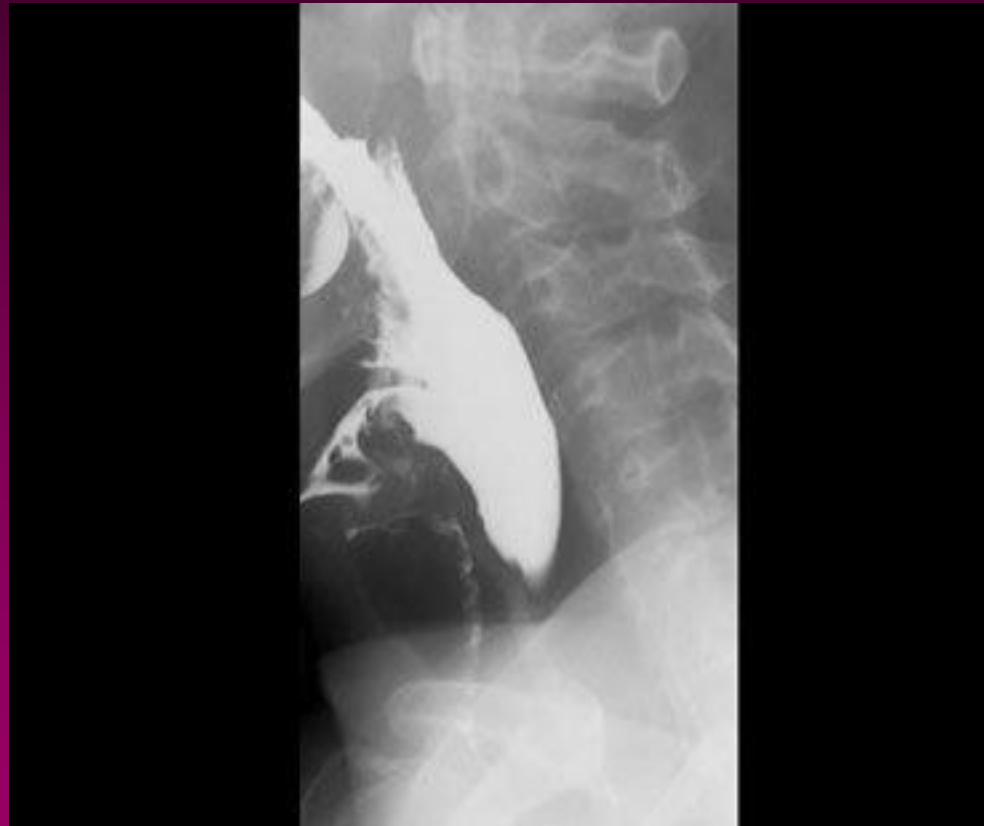Aspiration



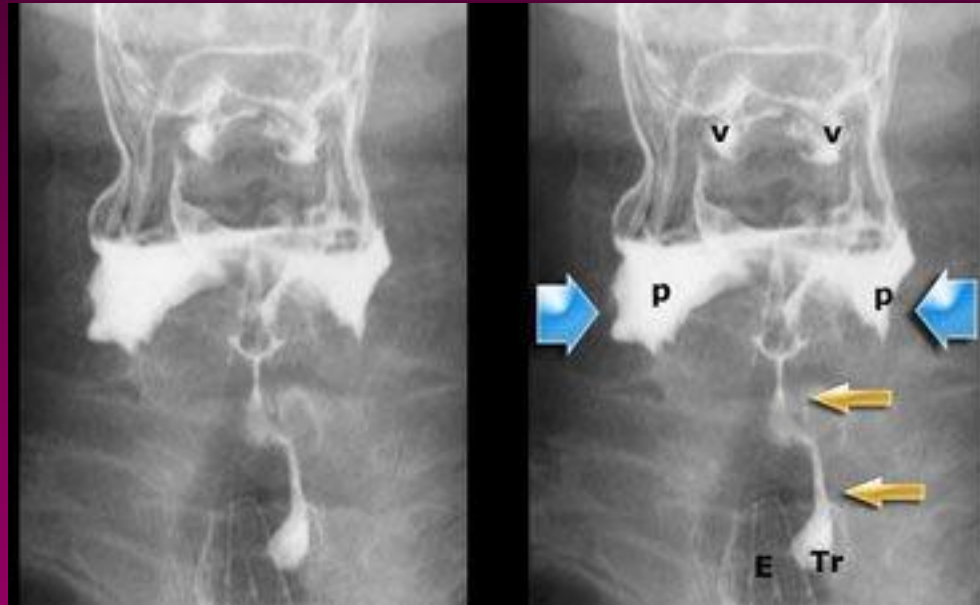
Aspiration before swallowing



Aspiration during swallowing



Aspiration from the Pyriform Sinuses



Non-Surgical Methods to Treat Aspiration

- Exercises
- Head position
 - Chin tuck, head lift, rotation of head
- Postural Compensation
 - Sitting upright, lying on side
- Swallow Retraining
- Diet Modifications

Surgical Treatments

- Cricopharyngeal myotomy
 - Useful if muscles are so weak the bolus cannot be propelled past cricopharyngeal sphincter
 - Useful if there is not complete relaxation of upper esophageal sphincter
 - Useful for abnormal increased muscular contractions during relaxation period

Surgical Treatments

- Percutaneous Gastrstomy Tube
 - Still allows patients to eat orally what they can eat safely
 - Can be removed if symptoms resolve

Neuromuscular Electrical Stimulation

- VitalStim approved by the FDA to treat dysphagia in 2002
- Small electrical impulses applied to skin overlying throat muscles
- Speech therapists determine the proper placement and then give the patient exercises to do during stimulation
 - So difficult to separate out treatment effect from therapy effect

Neuromuscular Electrical Stimulation

- Treatments are very safe
- Best studied in stroke patients.
 - Limits outcome assessments because stroke patients have spontaneous recovery
 - Placebo controlled studies have been small and failed to show a benefit
 - However one study of chronic dysphagia in stroke patients showed a very early improvement in swallowing with electrodes on

Neuromuscular Electrical Stimulation in Myositis

- Literature cited by VitalStim references only their FDA data for myositis
 - 8/892 patients in data filed with FDA had myopathy.
 - So no conclusive evidence it works in myositis
 - Therapy is clearly helpful

Conclusions

- Dysphagia is a common complication of myositis
 - Other causes as well that may be treatable as well
- Evaluation and therapy can help prevent significant morbidities
 - Weight loss
 - Aspiration
 - Malnutrition